

Atrophic rhinitis

A review

March 3, 2012 · Rhinology

Authors

Balasubramanian Thiagarajan

Abstract

Atrophic rhinitis is a chronic embarrassing debilitating disease involving nasal cavity and paranasal sinuses. It is characterized by foul smelling crusts (greenish) inside the nasal cavity. Nasal mucosa tends to bleed when these crusts are removed. Nasal cavity appears to be excessively roomy. Foul stench emanates from the patient. Patient is mercifully unaware of this stench because of the presence of anosmia. This article discusses the various features of this disease and the various management modalities available.

Atrophic rhinitis a review

Introduction:

Atrophic rhinitis is defined as a chronic nasal disease characterised by progressive atrophy of the nasal mucosa along with the underlying bones of turbinates. There is also associated presence of viscid secretion which rapidly dries up forming foul smelling crusts. This fetid odor ¹is also known as ozaena. The nasal cavity is also abnormally patent. The patient is fortunately unaware of the stench emitting from the nose as this disorder is associated with merciful anosmia². This disease is rather rare in developed countries, but are rather common in developing countries ³. Now a days it is more common as a sequelae of medical interventions. Overzealous turbinate surgery has been implicated as a probable iatrogenic cause.⁴

Synonyms:

The following are the various terminologies used to indicate the same condition:

1. Rhinitis sicca
2. Dry rhinitis
3. Ozena
4. Open nose syndrome
5. Empty nose syndrome

History:

It was Spenser Watson of London who first coined the term Ozena to describe this condition. He was the first to describe clinical features of this disease. He classified this disease into mild, moderate and severe varieties. Mild variety of atrophic rhinitis according to Watson is characterized by heavy crusting. These crusts can easily be removed by nasal douching. Moderate variety features anosmia and stench emanating from the nasal cavity. Severe variety is invariably caused by syphilis. Bone

destruction and cosmetic deformities of nose is rather common in this variety.³In 1876 Dr Bernhard Fraenkel first described the classic triad of symptoms which was virtually diagnostic of this disorder. This triad is still known as Fraenkel's triad in his honor include: Feter, Crusting and Atrophy of nasal structures. Frank Bosworth in 1881 noted that '*Breath from these patients were not only unpleasant but virtually unbearable. The sufferer perse was mercifully unaware because of the presence of anosmia.*'

Etiology:

The etiology of this problem still remains obscure. Numerous pathogens⁵ have been associated with this condition, the most important of them are:

1. Coccobacillus
2. Bacillus mucosus
3. Coccobacillus foetidus ozaenae
4. Diptheroid bacilli
5. Klebsiella ozaenae.

These organisms despite being isolated from the nose of diseased patients have not categorically been proved as the cause for the same.

Other predisposing factors include:

1. Chronic sinusitis -SSali⁶ considered atrophic rhinitis to be infective in nature. He reported atrophic rhinitis in 7 children of a family after a child with atrophic rhinitis spent a night in their house. Common organism isolated from nasal cavities of these children was Klebsiella ozenae
2. Excessive surgical destruction of the nasal mucosa and turbiantes
3. Nutritional deficiencies: Bernat⁷ in 1965 demonstrated that 50% of patients with atrophic rhinitis benefited with iron therapy. Han-sen⁸ demonstrated symptomatic improvement in majority of this patients with atrophic rhinitis when treated with vitamin A.
4. Syphilis.
5. Endocrine imbalances (Disease is known to worsen with pregnancy / menstruation)
6. Heredity: This was first reported by Barton and Sibert⁹ (Autosomal dominant pattern of inheritance identified).
7. Autoimmune disease
8. Developmental: Hagrass¹⁰ reported shortened Antero Posterior nasal lengths and poor maxillary antral pneumatization in patients with atrophic rhinitis.
9. Vascular: Excess sympathetic activity was observed in these patients by Ruskin

Age of onset:

Usually atrophic rhinitis commences at puberty.²

Sex predilection:

Females are more commonly affected than males

Classification of Atrophic rhinitis:

Primary atrophic rhinitis: This classic form of atrophic rhinitis is supposed to arise de novo. This is in fact a diagnosis of exclusion. This type of atrophic rhinitis is common in China, India and Middle East. In almost all these patients *Klebsiella ozenae* has been isolated.

Secondary atrophic rhinitis: This is the most common form of atrophic rhinitis seen in developed countries. In this type the predisposing cause is clearly evident. Common causes of secondary atrophic rhinitis include:

1. Surgical procedures involving nose and paranasal sinuses – They include turbinectomies, sinus surgeries, maxillectomy etc.
2. Irradiation
3. Trauma
4. Granulomatous diseases: Include Sarcoidosis, Leprosy and Rhinoscleroma
5. Infections: This includes tuberculosis and syphilis

Clinical features:

The presenting symptoms are commonly nasal obstruction and epistaxis. Anosmia i.e. merciful may be present making the patient unaware of the smell emanating from the nose. These patients may also have pharyngitis sicca. Choking attacks may also be seen due to slippage of detached crusts from the nasopharynx into the oropharynx. These patients also appear to be dejected and depressed psychologically.

Clinical examination of these patients show that their nasal cavities filled with foul smelling greenish, yellow or black crusts, the nasal cavity appear to be enormously roomy. When these crusts are removed bleeding starts to occur.

Why nasal obstruction even in the presence of roomy nasal cavity?²

This interesting question must be answered. The nasal cavity is filled with sensory nerve endings close to the nasal valve area. These receptors sense the flow of air through this area thus giving a sense of freeness in the nasal cavity. These nerve endings are destroyed in patients with atrophic rhinitis thus depriving the patient of this sensation. In the absence of these sensation the nose feels blocked.

Radiologic features of atrophic rhinitis:

Radiologic features are similar for both types of atrophic rhinitis. Plain xrays show lateral bowing of nasal walls, thin or absent turbinates and hypoplastic maxillary sinuses.

CT scan findings:

1. Mucoperiosteal thickening of paranasal sinuses
2. Loss of definition of osteomeatal complex due to resorption of ethmoidal bulla and uncinate process
3. Hypoplastic maxillary sinuses
4. Enlargement of nasal cavity with erosion of the lateral nasal wall

5. Atrophy of inferior and middle turbinates

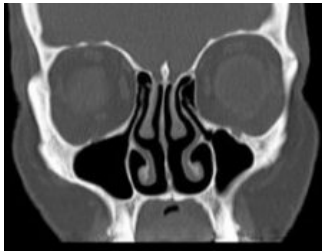


Fig. 1: CT scan nose and sinuses in a patient with atrophic rhinitis

Histopathological features:

1. Metaplasia of ciliated columnar nasal epithelium into squamous epithelium.
2. There is a decrease in the number and size of compound alveolar glands
3. Dilated capillaries are also seen

Pathologically atrophic rhinitis has been divided into two types:

Type I: is characterised by the presence of endarteritis and periarteritis of the terminal arterioles. This could be caused by chronic infections. These patients benefit from the vasodilator effects of oestrogen therapy.

Type II: is characterised by vasodilatation of the capillaries, these patients may worsen with estrogen therapy. The endothelial cells lining the dilated capillaries have been demonstrated to contain more cytoplasm than those of normal capillaries and they also showed a positive reaction for alkaline phosphatase suggesting the presence of active bone resorption. It has also been demonstrated that a majority of patients with atrophic rhinitis belong to type I category.

Management:

Conservative:

Nasal douching – The patient must be asked to douche the nose atleast twice a day with a solution prepared with:

Sodium bicarbonate – 28.4 g

Sodium diborate – 28.4 g

Sodium chloride – 56.7 g

mixed in 280 ml of luke warm water.

The crusts may be removed by forceps or suction. 25% glucose in glycerin drops can be applied to the nose thus inhibiting the growth of proteolytic organism.

In patients with histological type I atrophic rhinitis oestradiol in arachis oil 10,000 units/ml can be used as nasal drops.

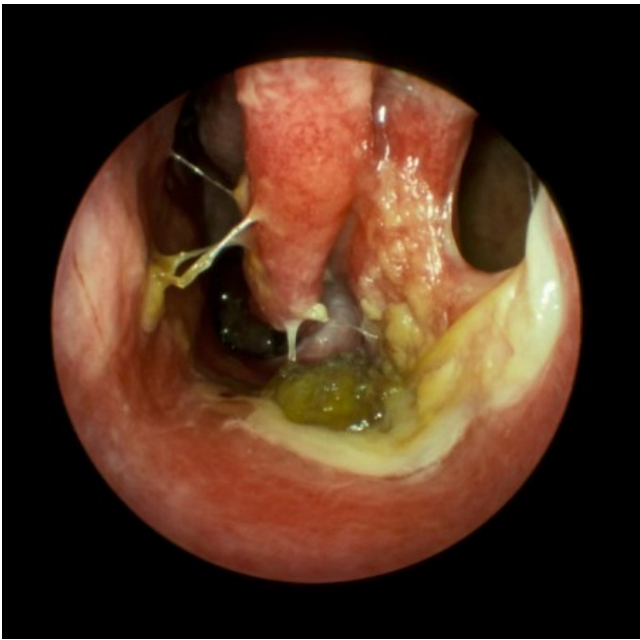
Kemecetine antiozaena solution – is prepared with chloramphenicol 90mg, oestradiol dipropionate 0.64mg, vitamin D2 900 IU and propylene glycol in 1 ml of saline.

Potassium iodide can be prescribed orally to the patient in an attempt to increase the nasal secretion.

Systemic use of placental extracts have been attempted with varying degrees of success.

Surgical management:

1. Submucous injections of paraffin, and operations aimed at displacing the lateral nasal wall medially. This surgical procedure is known as Lautenslauger's operation.
2. Recently teflon strips, and autogenous cartilages have been inserted along the floor and lateral nasal wall after elevation of flaps.
3. Wilson's operation – Submucosal injection of 50% Teflon in glycerin paste.
4. Repeated stellate ganglion blocks have also been employed with some success
5. Young's operation¹¹ – This surgery aims at closure of one or both nasal cavities by plastic surgery. Young's method is to raise folds of skin inside the nostril and suturing these folds together thus closing the nasal cavities. After a period of 6 to 9 months when these flaps are opened up the mucosa of the nasal cavities have found to be healed. This can be verified by postnasal examination before revision surgery is performed. Modifications of this procedure has been suggested (modified Young's operation) where a 3mm hole is left while closing the flaps in the nasal vestibule. This enables the patient to breath through the nasal cavities. It is better if these surgical procedures are done in a staged manner, while waiting for one nose to heal before attempting on the other side.



Atrophic rhinitis endoscopic view

References

1. Zohar Y, Talmi YP, Strauss M, et al. Ozena revisited. J Otol 19:345-9, 1990
2. http://www.drtbalu.co.in/atro_rhinitis.html
3. <http://www.utmb.edu/otoref/grnds/Atrophic-Rhinitis-050330/Atrophic-Rhinitis-050330.htm>
4. Atrophic rhinitis a review of 242 cases Moore, Eric J.; Kern, Eugene B American Journal of Rhinology, Volume 15, Number 6, November-December 2001 , pp. 355-361(7)
5. Dudley JP. Atrophic rhinitis: antibiotic treatment. Am JOtolaryngol 8: 387-90, 1987
6. Ssali CH. Atrophic rhinitis. A new curative surgical treatment. J Laryngol Otol 1973;87:397-403.

7. Bernat, I., Ozaena, A manifestation of iron deficiency, Oxford; Pergmon Press (1965)
8. Han-sen C. The ozena problem: clinical analysis of atrophic rhinitis in 100 cases. *Acta Otolaryngol* 1982; 93:461-4
9. Primary atrophic rhinitis: an inherited condition? R. P. E. Barton¹ and J. R. Sibert² *The Journal of Laryngology & Otology* (1980), 94 : pp 979-983 Copyright © JLO (1984) Limited 1980 DOI: 10.1017/S0022215100089738
10. Hagrass MAE, Gamae AM, el-Sherief SG, et al. Radiological and endoscopic study of the maxillary sinus in primary atrophic rhinitis. *J Laryngol Otol* 106: 702-3, 1992.
11. Young, A (May 1967). "Closure of the Nostrils in Atrophic Rhinitis". *The Journal of Laryngology & Otology* 81 (5): 515–524. doi:10.1017/S0022215100067426. PMID 6024992

☺