

Role of x-rays in Rhinology

Balasubramanian Thiagarajan

Stanley Medical College

Abstract:

X-rays in the present day context is considered to be outdated by Rhinologists. CT scan images have replaced conventional x-ray imaging. Current concensus is that still x-rays have a role in the field of rhinology. Its inherent advantages like easy availability, cost effectiveness makes this investigation still relevant in the present day scenario. Bony lesions involving nose and sinuses, can be evalutated with reasonable degree of accuracy by performing conventional radiographs. Air present inside the paranasal sinuses serve as excellent contrast medium for plain x-ray evaluation. Pathologies involving paranasal sinuses encroach upon these air spaces causing alterations in their translucency.

Introduction:

With the advent of CT / MRI imaging plain radiographs are losing their relevance as far as rhinological diagnosis is concerned. This article attempts to explore the currently prevailing indications for the use of plain radiographs in rhinology. Eventhough CT scan provides improved resolution of soft tissue densities it has its own draw backs like increased cost of investigation and not so easy availability. Paranasal sinuses are air filled cavities. Pathology involving these structures cause varying degrees of attenuation of these air contrast medium which can easily be observed in any conventional radiographs. Certain pathological conditions can cause accumulation of fluid within the sinus cavity. This can be clearly demonstrated if plain x-rays are taken with patient in erect position. Fluid levels can clearly be demonstrated even in plain radiographs.

Advantages of x-ray imaging in rhinology include:

1. Cost effectiveness of the investigation
2. Easy availability
3. Currently available digital x-ray imaging techniques provide better soft tissue and bone resolution when compared to conventional x-rays

Disadvantages of conventional radiographs:

1. Plain radiographs have a false positive rate of 4% ¹.

2. Plain radiographs have false negative rate of more than 30% ².
3. Difficulties in patient positioning

Standard radiograph positions for studying nose and paranasal sinuses:

Radiographic study of paranasal sinuses are standardized around three positions. These include:

1. Two anatomical positions – Coronal and sagittal
2. Radiographic – This position pertains to radiographic baseline. This is actually an imaginary line drawn from the outer canthus of the eye to the mid point of external auditory canal.

Positions used to study paranasal sinuses include:

1. Occipito mental view (water's view)
2. Occipital frontal view (Caldwell view)
3. Submento-vertical view (Hirtz view)

Water's view:

Also known as occipito mental view is the commonest view taken. This view was developed by Waters and Waldron in 1915. This was actually a modification of occipito frontal projection (Caldwell view) ³. Patient is made to sit facing the radiographic base line tilted to an angle of 45 degrees to the horizontal making the sagittal plane vertical. The radiological beam is horizontal and is centered over a point 1 inch above the external occipital protuberance. In obese patients with a short neck it is virtually impossible to obtain an angulation of 45 degrees. These patients must be made to extend the neck as much as possible and the xray tube is tilted to compensate for the difference in angulation. The mouth is kept open and the sphenoid sinus will be visible through the open mouth. If the radiograph is obtained in a correct position the skull shows a foreshortened view of the maxillary sinuses, with the petrous apex bone lying just beneath the floor of the maxillary antrum. In this view the maxillary sinuses, frontal sinuses and anterior ethmoidal sinuses are seen. The sphenoid sinus can be seen through the open mouth.

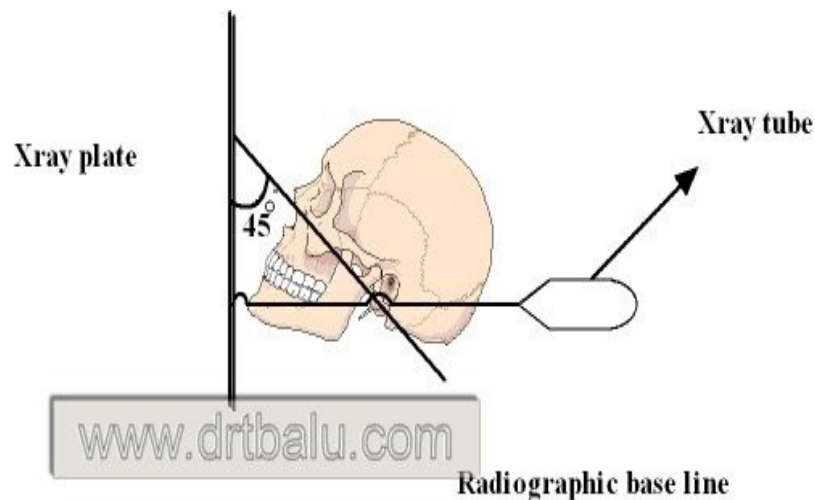


Diagram showing the position of the skull while taking x-ray sinus water's view

If the antrum in water's view demonstrates a loss of translucency which could be an indicator of fluid level, then another x ray is taken with a tilt of sagittal plane to an angle of 30 degrees. This view will clearly demonstrate movement of fluid to a new position. In this view the fluid moves towards the lateral portion of the antrum where it can clearly be seen.

In x-ray paranasal sinuses water's view chronic maxillary sinusitis is displayed as:

1. Clouding of maxillary sinuses
2. Opacification of maxillary sinuses
3. Mucosal thickening of maxillary sinuses
4. Fluid level seen in the maxillary sinuses

Among these 4 signs least accurate happens to be clouding of maxillary sinuses. This has a false positive value of more than 30% in some studies. Total opacification of maxillary sinus is a more reliable sign of infection with accuracy levels ranging between 80-92%⁴.

Sources for error in interpreting xray paranasal sinuses waters view could be:

1. Anatomical
2. Technical

Anatomical causes for interpretation errors in xray paranasal sinuses water's view:

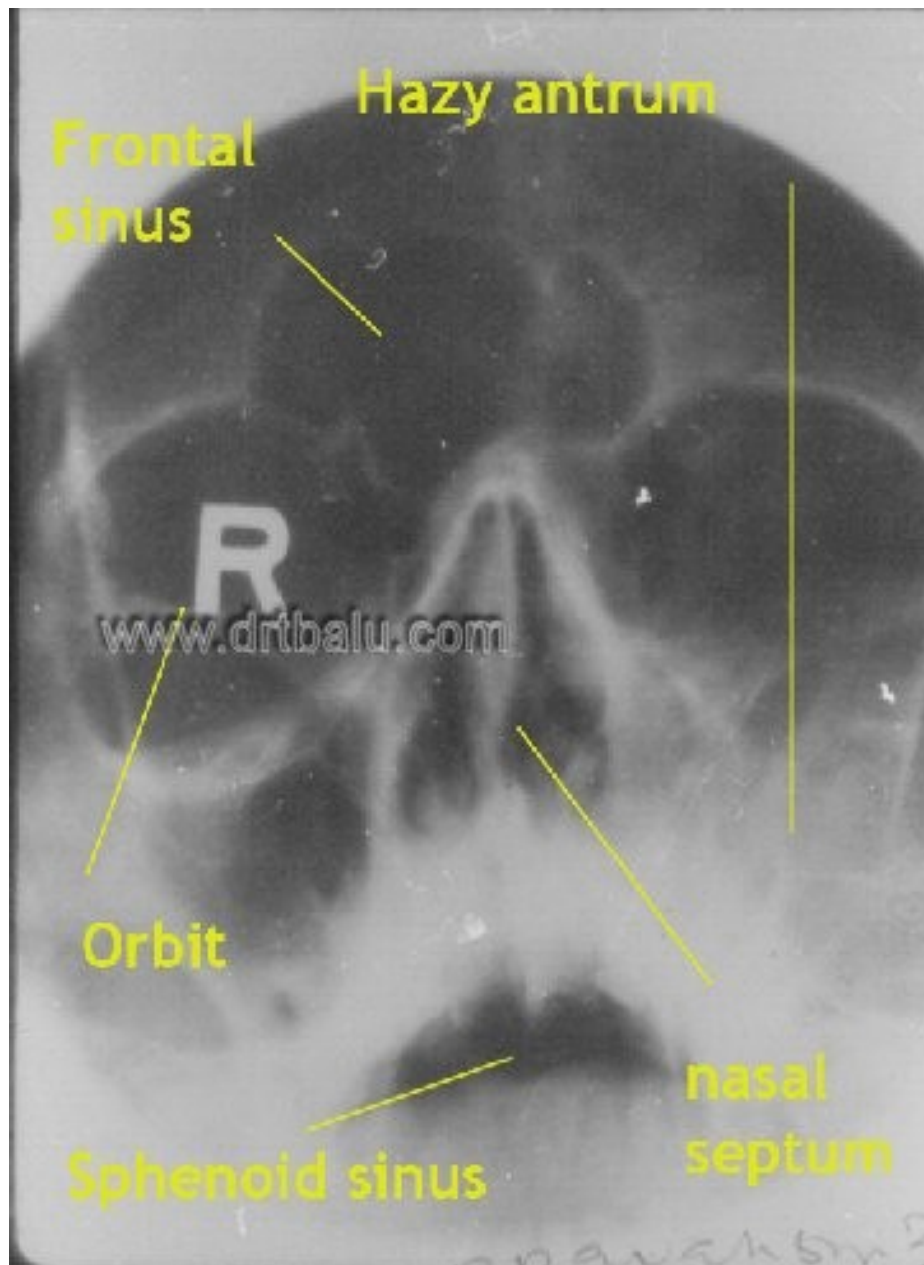
1. Hypoplastic sinus – This could cause clouding / total opacification of maxillary sinus
2. Orbital floor exposure- This could appear as false mucosal thickening
3. Zygomatic recess – This could appear as false mucosal thickening
4. Superior orbital fissure- This could appear as false mucosal thickening or false interpretation as fluid level.

Technical causes for interpretation errors in x-ray paranasal sinuses water's view include:

1. Soft exposure – This can cause an impression of clouding of maxillary sinuses
2. Lateralization of radiographic tube – This will cause mucosal thickening on the side of lateralization to be missed in the radiograph.
3. Inadequate tilting of tube / head – This will cause an artificial impression of presence of fluid level.
4. Marked tilting of tube / head – This will cause impression of clouding of maxillary sinuses
5. Patient in recumbent position – This can cause retained secretions in the maxillary sinuses to be missed.

X-ray paranasal sinuses Water's view clearly shows:

1. Maxillary sinuses
2. Frontal sinus
3. Ethmoidal sinuses
4. Orbit
5. Sphenoid sinus
6. Nasal cavities
7. Alveolar arches
9. Xygoma



X-ray paranasal sinuses Water's view showing different structures and a hazy maxillary sinus on the left side

X-ray paranasal sinuses water's view is still a viable investigation in patients with facio maxillary trauma. Examination of Dolan's line in x-ray sinuses water's view helps in identifying patients with zygomatico-maxillary complex fractures.

Dolan's line:

This was first popularized by Dolan et al. They described three lines which in conjunction resembled elephant's head in profile.

1. Orbital line – This resembles the elephant's ear. Disruption of this line could be

due to fracture through lateral orbital rim or diastasis of fronto-zygomatic suture line. Disruption of inferior portion of orbital line could be due to fracture involving inferior rim of orbit / floor of orbit.

2. Zygomatic line – This line resembles elephant's forehead and trunk. This line follows the lateral orbital rim to the superior margin of zygomatic arch. Disruption of this line indicates fracture involving zygoma.

3. Maxillary line – This resembles elephant's chin and trunk. This line follows the lateral wall of the maxillary sinus to the inferior margin of zygomatic arch. Fractures are expected in this zone.

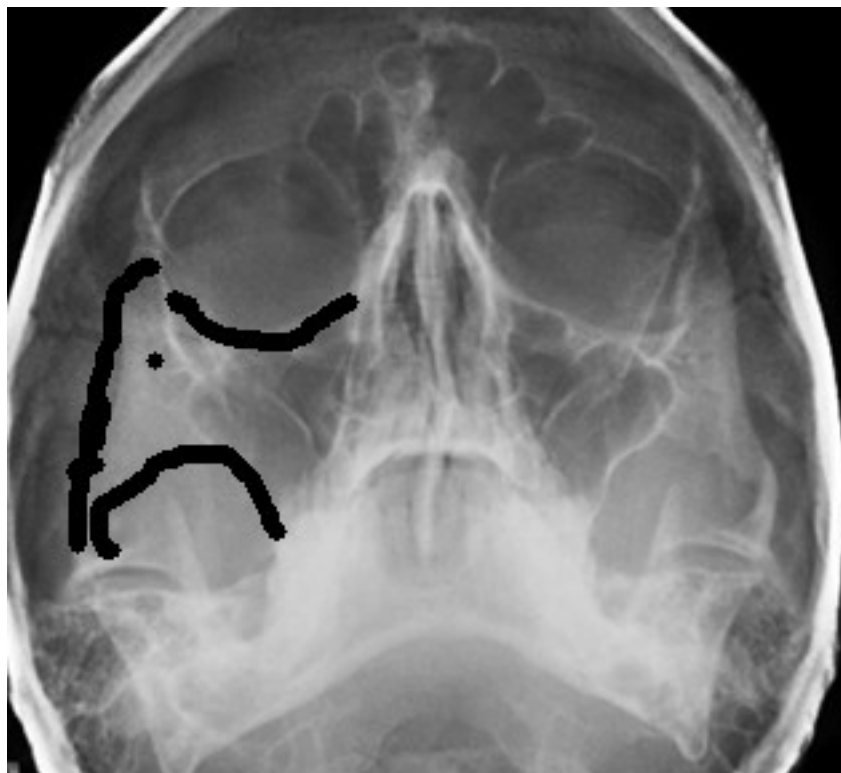
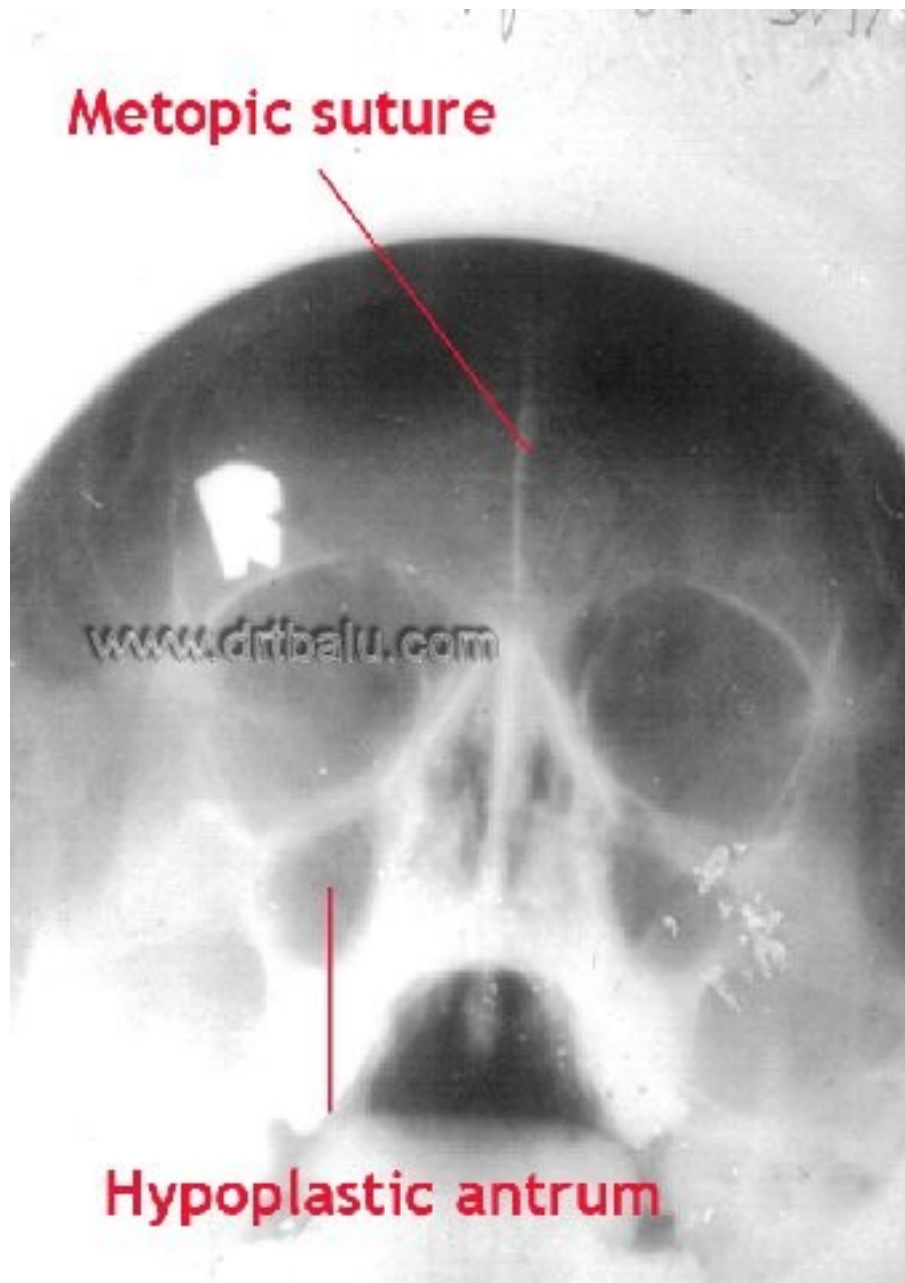


Image showing Dolan's line marked in x-ray sinuses Water's view

In x ray para nasal sinuses waters view the normal frontal sinus margins show scalloping. Loss of this scalloping is a classic feature of frontal mucocele. If frontal sinus is congenitally absent (agenesis) then a suture line known as the metopic suture is visible in the fore head area. Sometimes a pair of large anterior ethmoidal air cells may take up the place of frontal sinuses. Here too the metopic suture line is visible. This suture divides the two halves of frontal bone of the skull in infants and children. This suture usually disappears at the age of 6 when it fuses. If this suture is not present at birth it will cause a keel shaped deformity of the skull (trigonocephaly).



X-ray sinuses water's view showing Metopic suture with hypoplastic maxillary sinus and absent frontal sinus

Since hypoplastic antra are associated with sclerosis of its margins, it will be very difficult to perforate the medial wall of the antrum while performing antrostomy.

In conditions like malignancy involving the maxillary antrum X ray sinuses waters view shows the following features:

Expansion

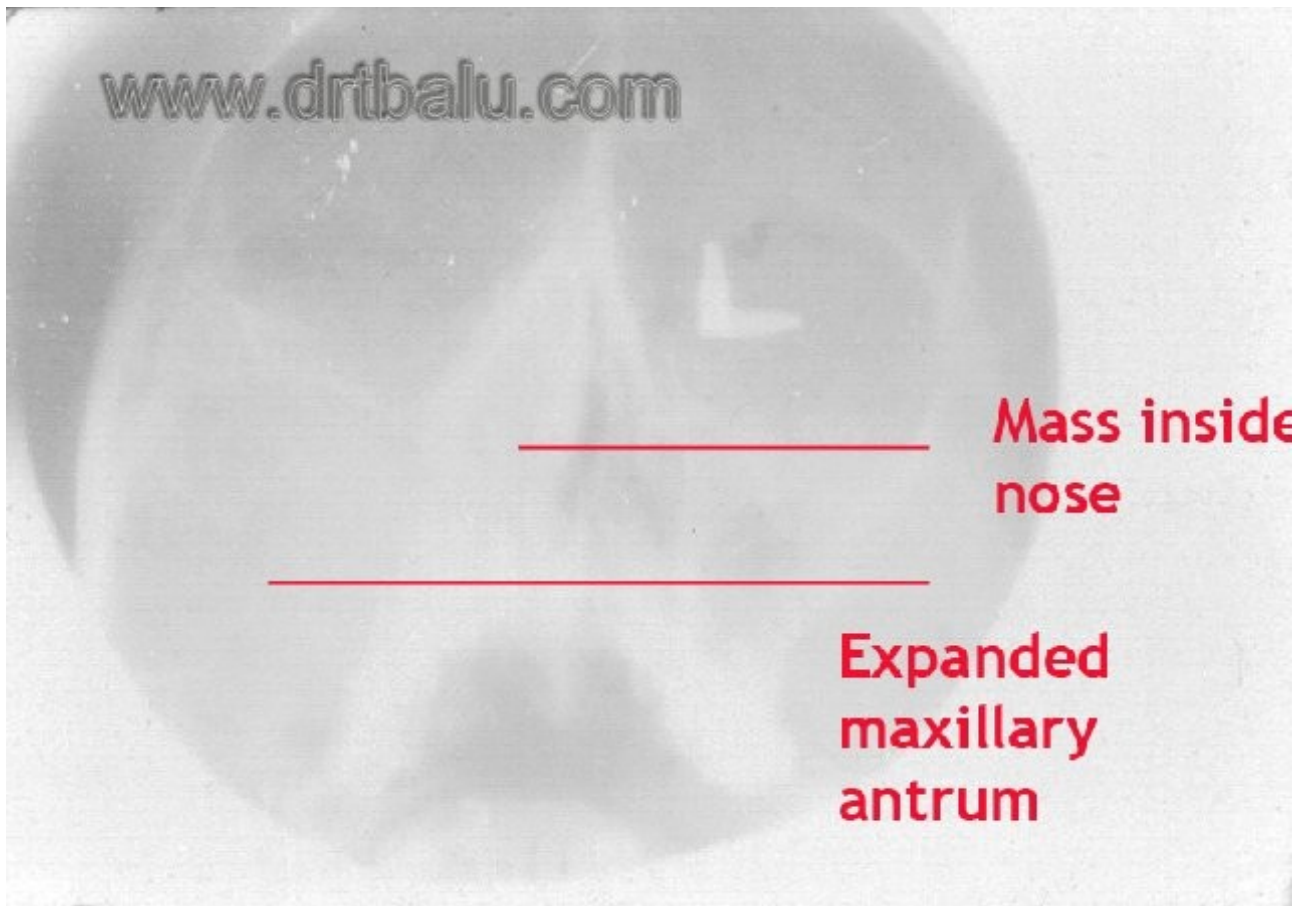
Erosion

Opacity.

Expansion is characterised by increase in the size of maxillary antrum when compared to its counter part on the opposite side.

Erosion may occur in the medial wall of the antrum or in its antero lateral wall. The canine fossa area is the thinnest portion of maxillary antrum antero lateral wall. Erosion is hence common in this area.

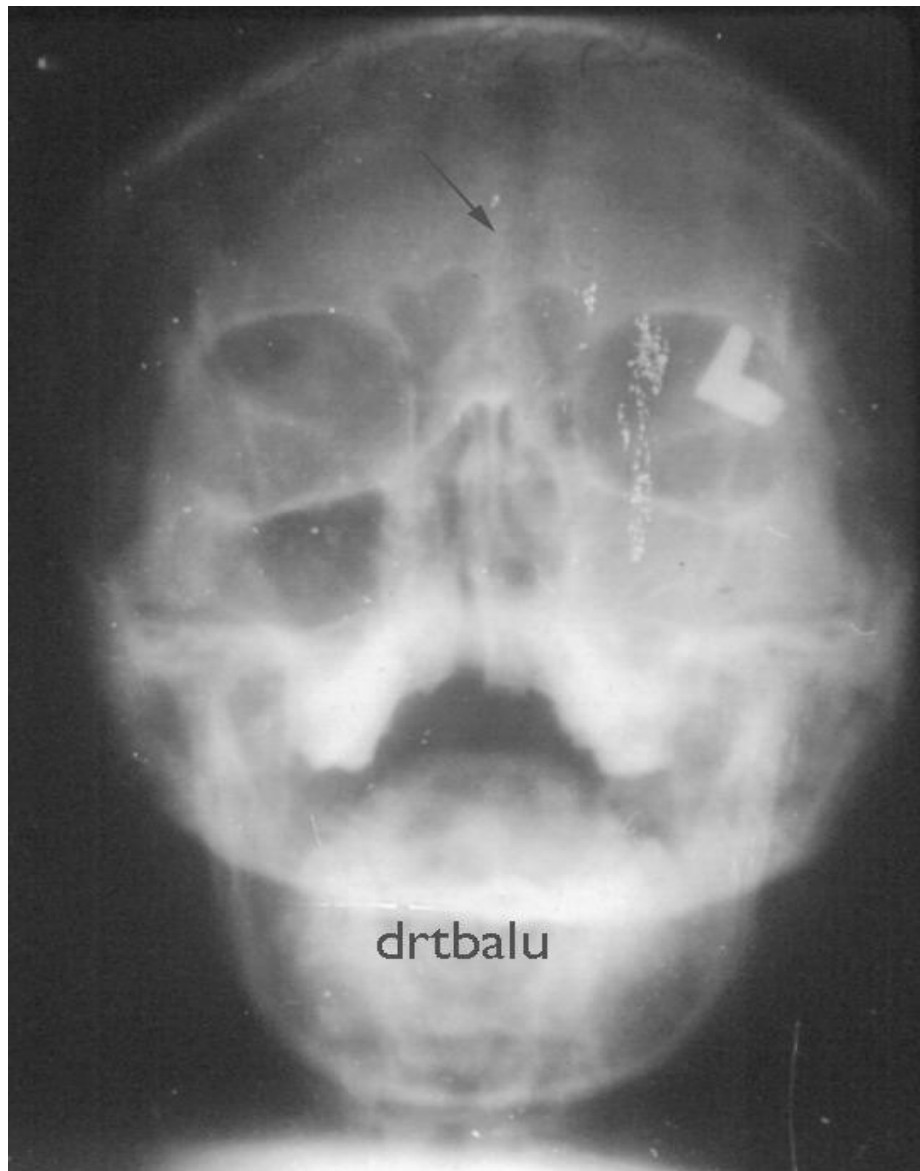
Opacity is the term used to describe a maxillary sinus antra involved with malignant growth. This opacity is due to the periosteal reaction due to malignant growth.



X-ray sinuses water's view showing expansion and erosion of right maxillary antrum due to malignancy

According to Veterans Affairs general medicine clinic study ⁵ using the following criteria to diagnose sinusitis from x-ray sinuses water's view improved its accuracy to more than 80%. These criteria include:

1. Presence of air fluid level
2. Sinus opacity
3. Mucosal thickening geater than 6 mm



X-ray PNS water's view shows metopic suture (arrow) which is a persistent frontal suture.

Usually it disappears at the age of 6 with the normal development of frontal sinuses. Persistence of Metopic suture (i.e. sutura frontalis persistens). In patients with agenesis of frontal sinuses the metopic suture is still persistent. In the above x-ray the frontal sinus is absent and is replaced by a pair of large anterior ethmoidal air cell. (Note: The left maxillary sinus appear hazy, possibly due to sinusitis).*

Routine CT scan imaging is not indicated routinely to diagnose patients with acute sinusitis. Eventhough it has high specificity in diagnosing acute sinusitis it has low specificity. Studies reveal that more than 40% of asymptomatic patients too show CT scan abnormalities indicating presence of sinusitis⁶.

Digital x-rays:

With the advent of digital imaging techniques the cost of imaging has drastically reduced. The quality of images generated are much better than analog ones which was captured on a film. In addition this procedure involves less amount of radiation to the patient when compared to that of conventional x-ray techniques.

Occipito-frontal view (Caldwell view):

This position is ideally suited for studying frontal sinuses. In this position the frontal sinuses are in direct contact with the film hence there is no chance for any distortion or geometric blur to occur. Hence it is ideally suited to create frontal sinus templates for external surgeries involving frontal sinuses.

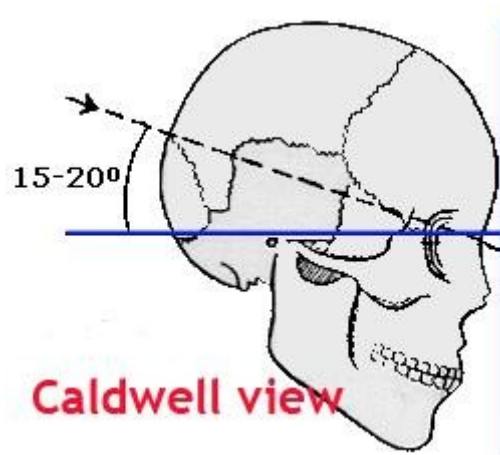
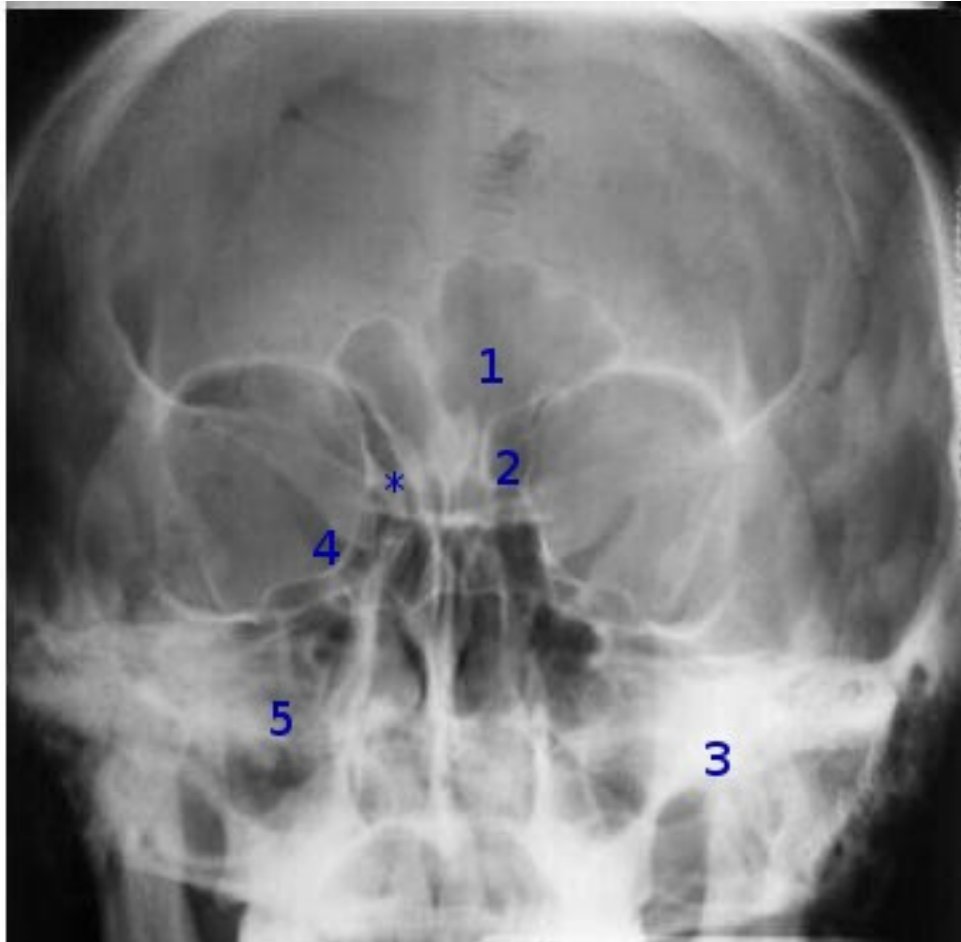


Figure showing patient position for Caldwell view radiograph

To get a Caldwell view the patient is made to sit in front of the film with the radiographic vbase line tilted to an angle of 15 - 20 degrees upwards. The incident beam is horizontal and is centered 1/2 inch below the external occipital protuberance. This view is also known as the frontal sinus view. In this view the petrous portion of the temporal bone obscures the visualization of maxillary sinuses. Frontal sinuses can be clearly studied using this view. This view also helps in templating the frontal sinus before external Fronto ethmoidectomy surgeries. This view also clearly demonstrates frontal and ethmoidal sinuses. Maxillary sinus is not clearly visible because the petrous apex obscures its view.

In this view a small indentation / groove can be seen along the upper portion of the medial wall of orbit. This groove is caused by anterior ethmoidal artery and nasociliary nerve. The ethmoido-maxillary plate is clearly seen in this view. This is actually a useful landmark for localizing spread of tumors.



X-ray sinuses Caldwell view:

- 1- Frontal sinus
- 2- Ethmoid sinus
- 3- Petrous apex
- 4- Inferior orbital fissure
- 5- Maxillary sinus obscured by petrous apex
- *- Site of anterior ethmoidal artery

Submentovertical view (Hritz view):

This view is primarily taken to view sphenoid sinus. Fluid levels in sphenoid sinuses are clearly shown in this view. To take an x ray in this position, the back of the patient is arched as far as possible so that the base of skull is parallel to the film. The x ray beam is centered in the midline at a point between the angles of the jaws. In elderly patients this view can be easier to achieve if carried out in the supine position with the head hanging back over the end of the table. This view also demonstrates the relative thicknesses of the bony walls of the antrum and the frontal sinuses.

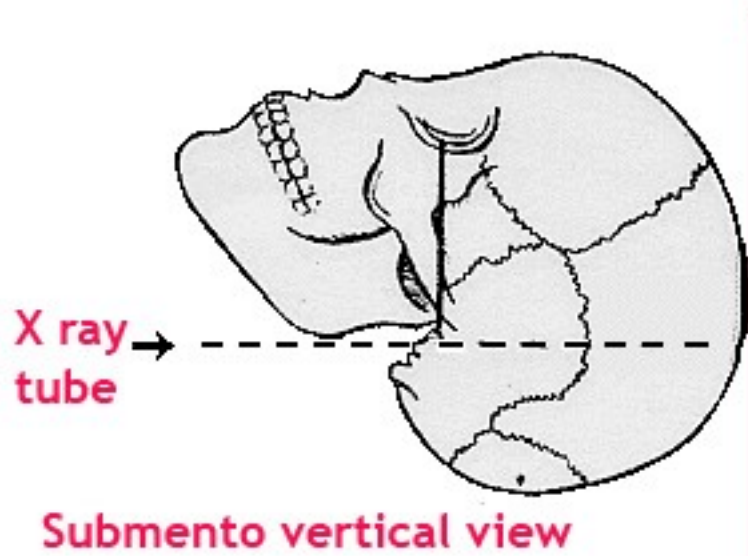
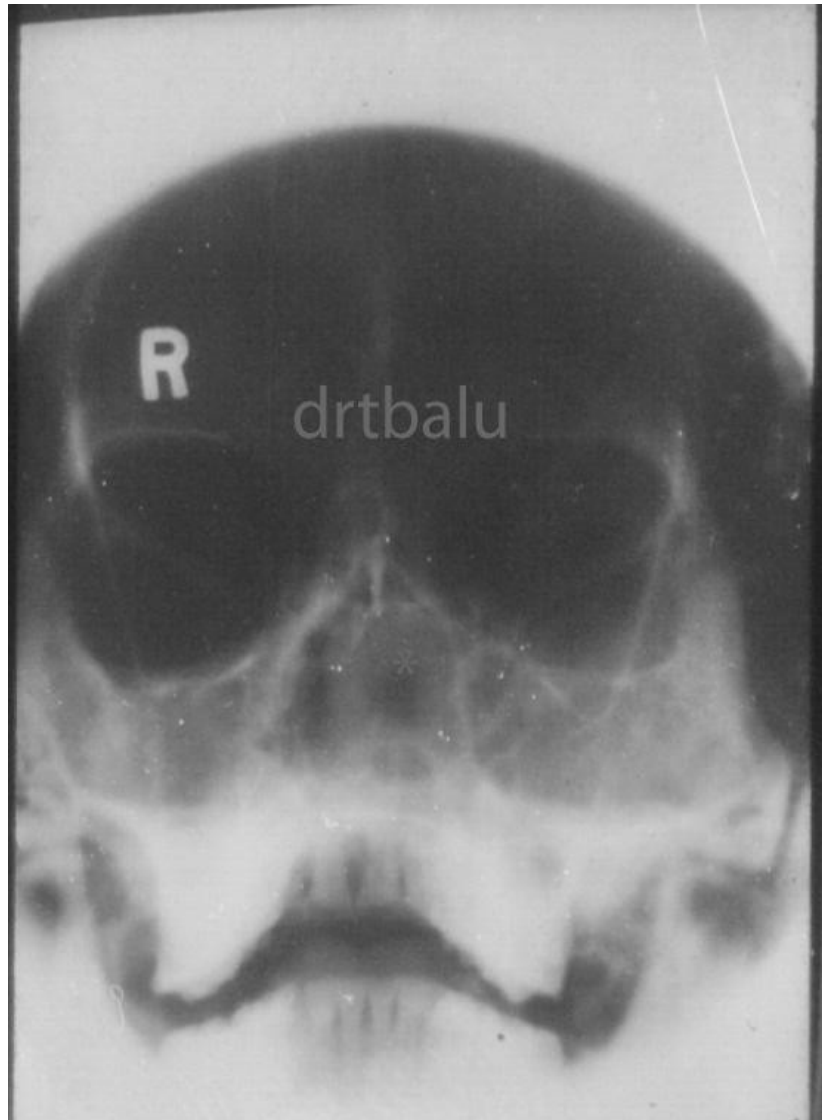


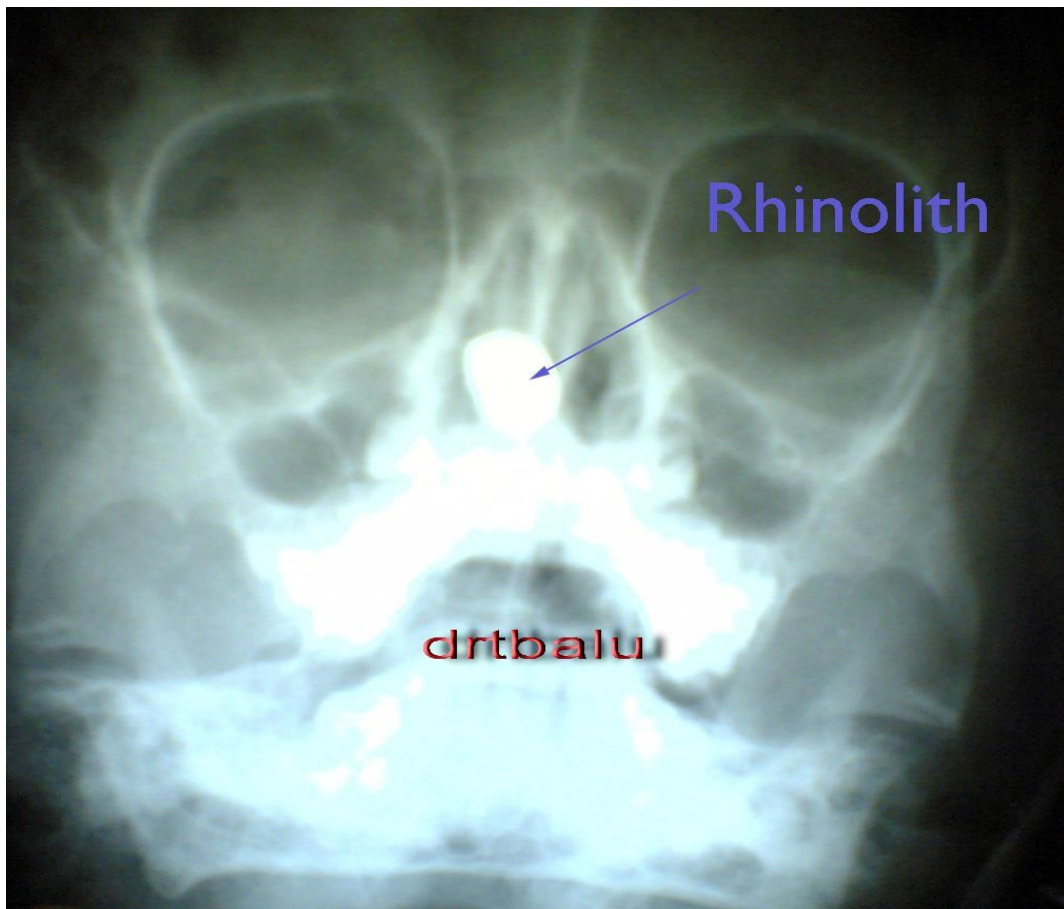Figure showing positioning of patient for submento-vertical view

Fluid levels in sphenoid sinus can be clearly seen in this view. Zygomatic arch can also be clearly delineated in this view. This view is not popular these days because CT scans give better resolution of this area. CT scans have largely replaced this view.

Some pathological conditions that are clearly seen in sinus radiographs:



In the x-ray shown above, a swelling could be seen in the nasal septal area. Gas shadow could also be seen inside the swelling. This gas shadow could be caused by gas released by pyogenic organisms. The cartilaginous portion of the nasal septum is not visible, could have been eroded. Probable diagnosis is septal abscess. Both the maxillary sinuses also appear hazy due to infection. Collection of pus between the Perichondrium and the nasal septal cartilage compromises the nutritional status of the cartilage as it is dependent on the Perichondrium for its nourishment. This cartilage undergoes necrosis. Septal abscess in this patient could have been caused by chronic sinus infection (i.e. Note haziness of both maxillary sinuses in this patient).



X-ray PNS showing radio – opaque shadow inside the nasal cavity possibly rhinolith

X-ray lateral view:

This view helps in diagnosing pathologies involving frontal sinuses. It helps in determining whether the loss of translucency is due to thickening of the anterior bony wall or infection of the frontal sinus per se. This view also demonstrates fluid levels in the antrum. This view also gives information on the naso pharynx and soft palate. This is infact a standard projection used to ascertain enlargement of adenoid tissue.

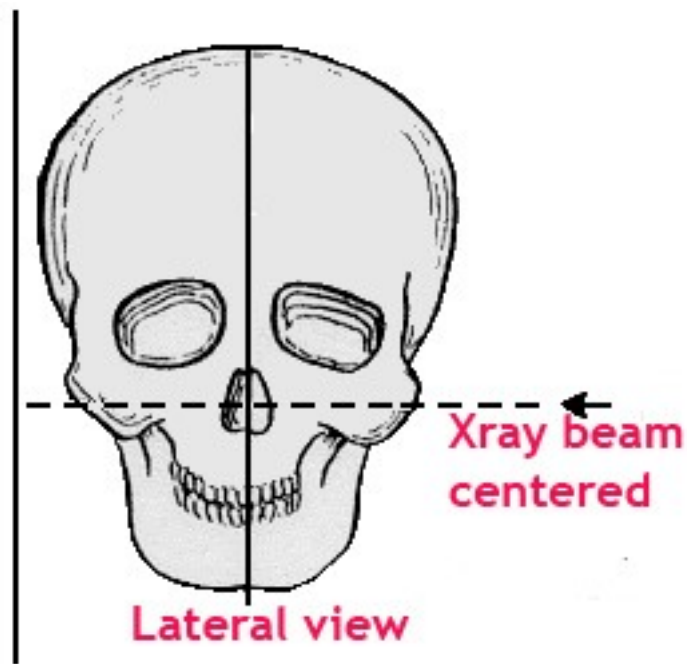
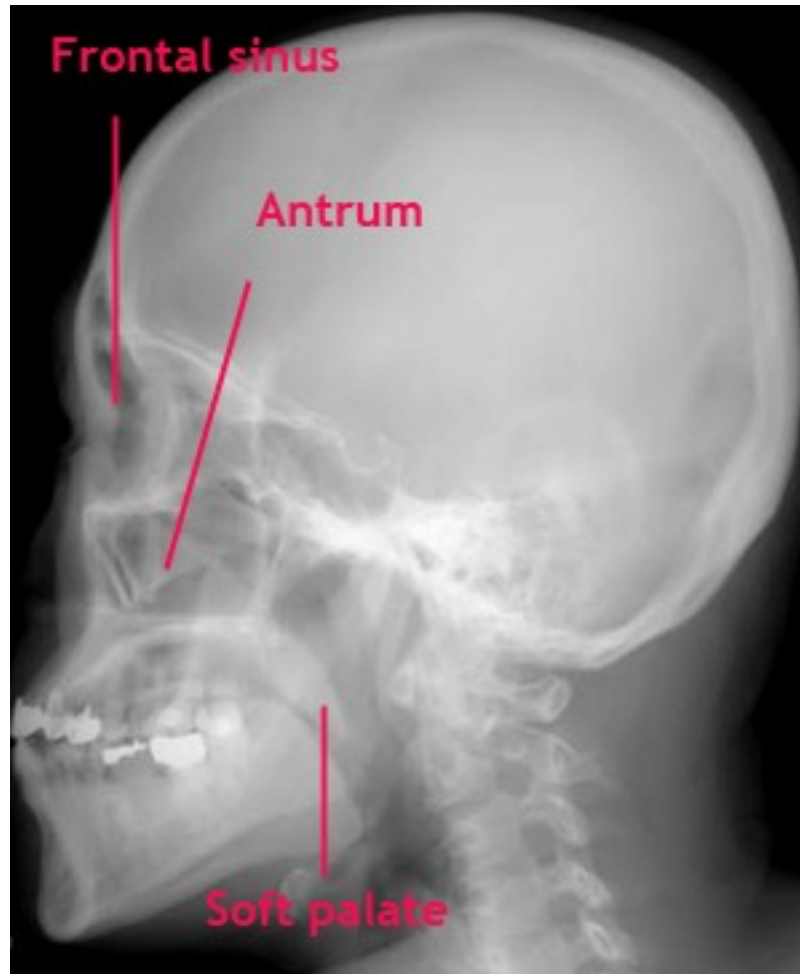

Figure showing skull position for xray skull lateral view

For this view the patient is made to sit with the sagittal plane parallel to the xray film and the radiographic base line is horizontal. The incident ray is horizontal and the incident beam is centered at the mid point of the antrum.



Xray skull lateral view

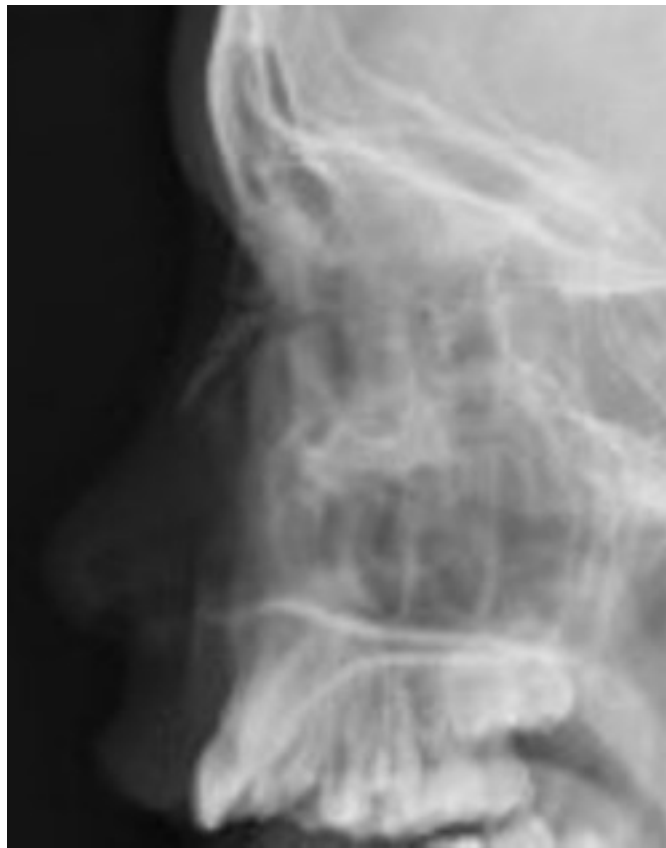Oblique view:

This view helps in demonstrating posterior ethmoid air cells and optic foramen. To obtain this projection the patient is made to sit facing the film. The head is rotated so that the sagittal plane is turned to an angle of 39 degrees. The radiographic base line is at an angle of 30 degrees to the horizontal. The incident beam is horizontal and is centered so that the beam passes through the centre of the orbit nearest to the film.

X-ray nasal bone:

This is usually taken to rule out nasal bone fractures. One should be cautioned against misinterpreting groove for nasociliary nerve which could mimic fracture. Fracture nasal bones is actually a clinical diagnosis based on the following findings:

1. Tenderness over nasal bone area
2. Crepitus over nasal bone area
3. Swelling and deformity over nasal bone area



X-ray nasal bones showing fracture line

References:

1. Axelson A , Grebelius N , Chidekel N , Jensen C . The correlation between radiology examination and irrigation findings in maxillary sinuses Acta otolaryngol (stockh) 1970 ; 90 : 302-6
2. Pfliederer AG , Drake – lee AB , Lowe D. ultrasound of the sinuses ; a worth while procedure ? A comparison of ultrasound and radiography in predicting

the findings of proof puncture on the maxillary sinuses .clin otolaryngol 1984 ;
9: 335-9

3. WATERS, C. A., and WALDRON, C. V. (1915) Roentgenology of the accessory nasal sinuses describing a modification of the occipitofrontal position. American Journal of Roentgenology, 2: 633-639.

4. BALLANTYNE, J. C , and ROWE, A. R. (1949) Some points in the pathology, diagnosis and treatment of chronic maxillary sinusitis. Journal of Laryngology and Otology, 63: 337-341.

5. Ros SP, Herman BE, AzarKia B. Acute sinusitis in children: is the Water's view sufficient? Pediatr Radiol. 1995;25:306-7.

6. Calhoun KH, Waggenpack GA, Simpson CB, Hokanson JA, Bailey BJ. CT evaluation of the paranasal sinuses in symptomatic and asymptomatic populations. Otolaryngol Head Neck Surg. 1991;104:480-3.